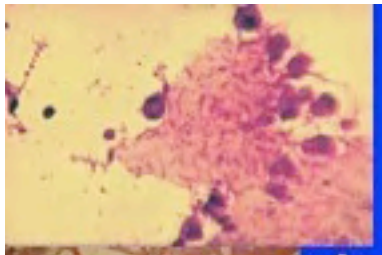

What is a biofilm?

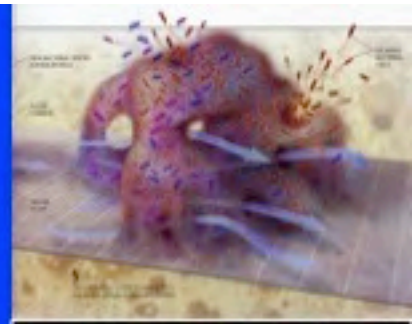

- Appearance - how does it look
- Where is it located/persists: Surface: - body - outer/inner
  Surface: - artificial
  Inside body

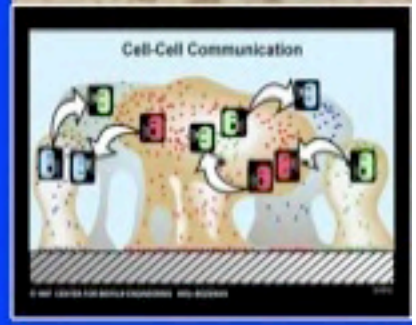

Gradients

- Physiology
- Biochemistry
- Genetics
- Resistance: To innate and adaptive defence mechanisms
  To antibiotics/disinfectants
- Pathology - pathogenesis - disease

Definition: A structured consortium of bacterial cells surounded by a self-produced polymer matrix, mono/polyspecies

BIOFILM INFECTION = Chronic infection = an infection which A) persists in spite of therapy, and in spite of the host's immune- and inflammatory response, and B) is characterized by persisting pathology and immune response (in contrast to colonization)

Some general features of biofilm infections in humans compared to acute planktonic infections and superficial colonozation/normal flora on skin and mucosal membranes. **The bold fonts indicate biofilm specific features**

Features of biofilm infections	Necessary condition for biofilm infections	Sufficient condition for biofilm infecions	Also found in acute planktonic infections	Also found in colonization/ normal flora on skin and mucosal membranes
Aggregates of bacteria embedded in a self-produced polymer matrix	Yes	Yes	No	No/Yes
Tolerant to clinical relevant PK/PD dosing of antibiotics in spite of susceptibility of planktonic cells	Yes	Yes	No	No/Yes
Tolerant to both innate and adaptive immune reponse	Yes	Yes	No	No/Yes - unknown (s-IgA)
Inflammation	Yes	No	Yes	No
Biofilm-specific antigens	No and Yes - seldom – e.g. P.seudomonas aeruginosa alginate	No and Yes - seldom – e.g. Pseudomonas aeruginosa alginate	No	No

(Høiby et al.:Antibiotic resistance of bacterial biofilms Internat. J. Antimicrob. Agents 35:322-32; 2010)

Some general features of biofilm infections in humans compared to acute planktonic infections and superficial colonozation/normal flora on skin and mucosal membranes. **The bold fonts indicate biofilm specific features**

Features of biofilm infections	Necessary condition for biofilm infections	Sufficient condition for biofilm infecions	Also found in acute planktonic infections	Also found in colonization/ normal flora on skin and mucosal membranes
Antibody response	Yes - after some weeks	No	Yes - after some weeks	No
Chronic infections	Yes	Yes	No	No
Foreign body associated infections	No	Yes	No but yes the first day of infection	No
Located on surfaces	No	No	Yes	Yes
Localized infetion	Yes	No	Yes	Yes
Focus for spreading or local exacerbation	Yes	No	Yes	Yes

(Høiby et al.:Antibiotic resistance of bacterial biofilms Internat. J. Antimicrob. Agents 35:322-32; 2010)

Endotracheal suction. Patients treated with artificial ventillation frequently develops Ventillator Associated Pneumonia (VAP)

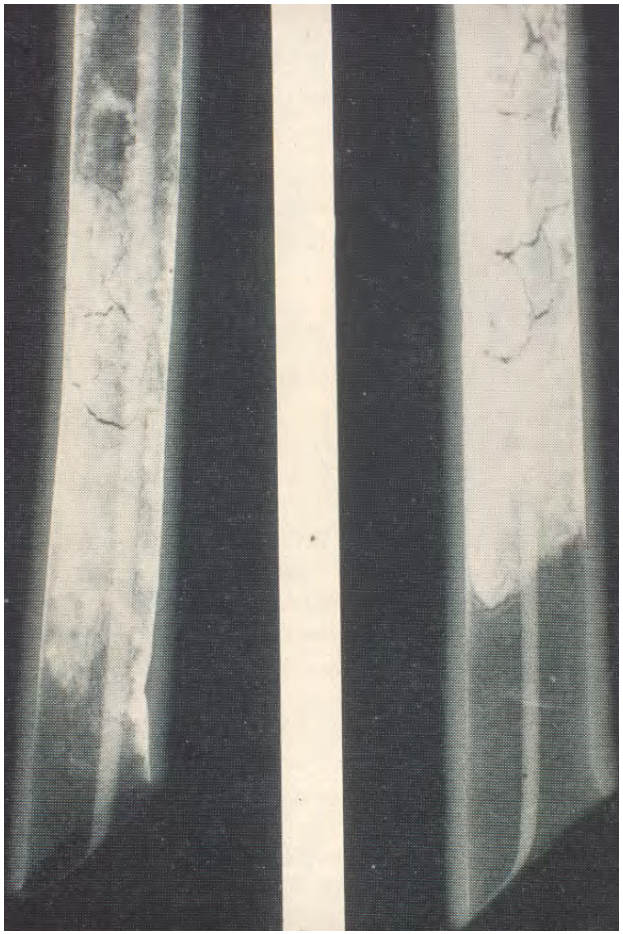

(Inglis: Evidence for Dynamic Phenomena in Residual Tracheal Tube Biofilm. Br J Anaesth1993:70:22-24)

VENTILLATOR ASSOCIATED PNEUMONIA



57 year man L.S., 3-7-03 biliary-pancreatic stent, biofilm was focus of E. coli sepsis 21-7-03, recurrent E. coli + K. oxytoca sepsis and death 12-8-03. Autopsy 14-8-03: Growth from biofilm: E. faecium, K. oxytoca, E. coli of same genotype as the blood isolate.

FESS in chronic CF patient – variation in operative findings

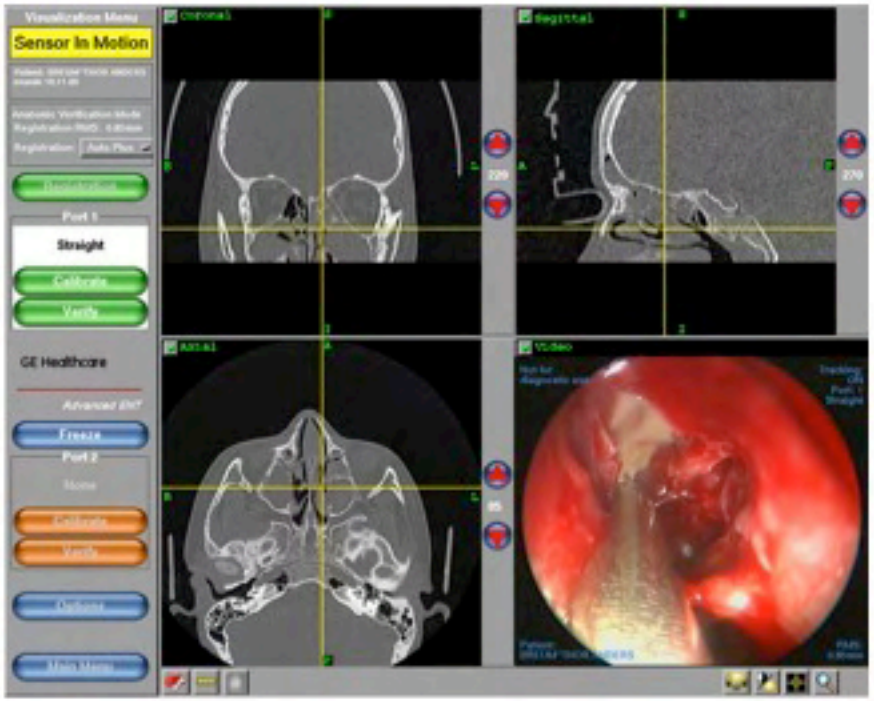

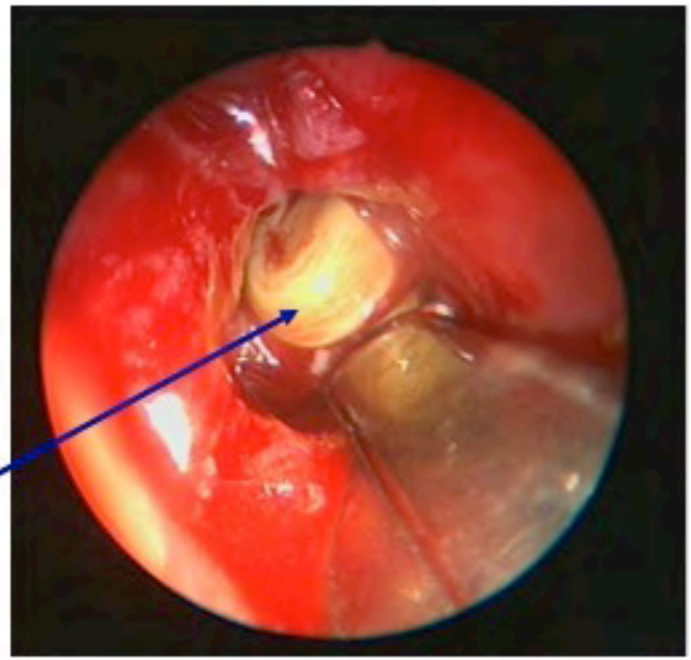

Thick pus from sinus maxillaris (CF 414)

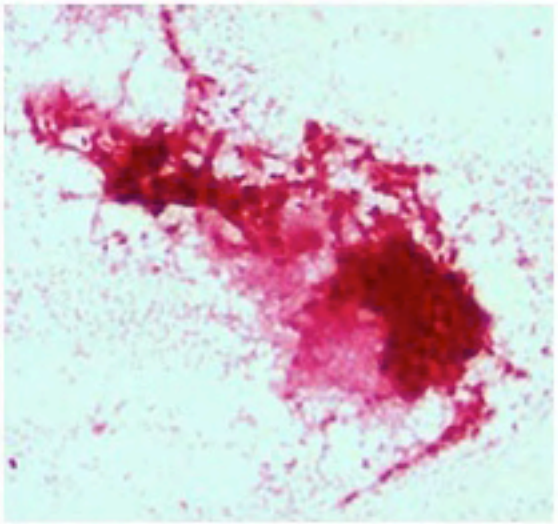

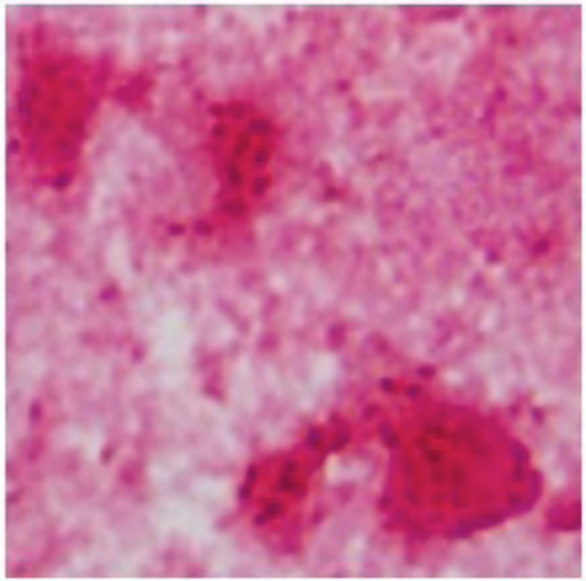

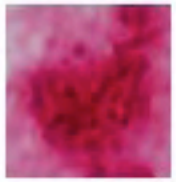

Sinus P. aeruginosa biofilms in CF – no PMNs!

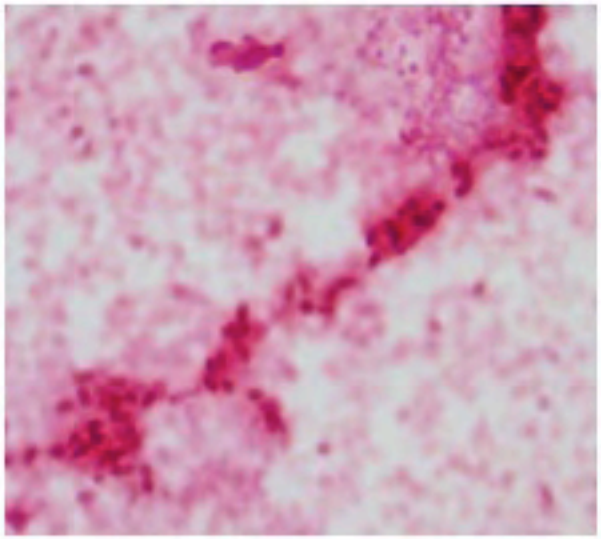

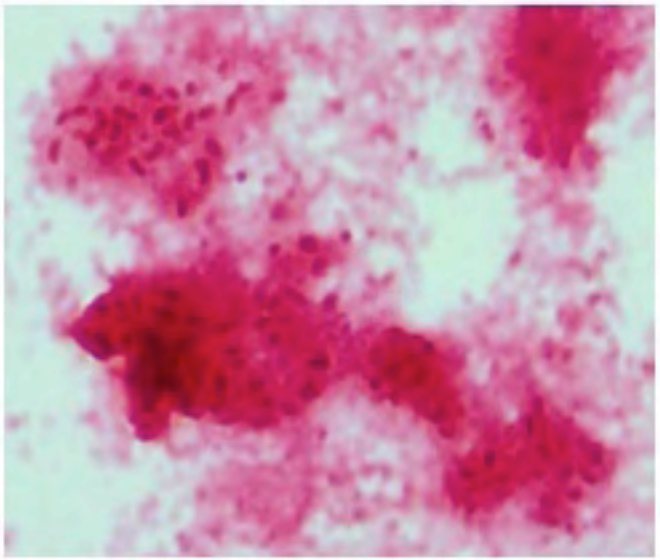

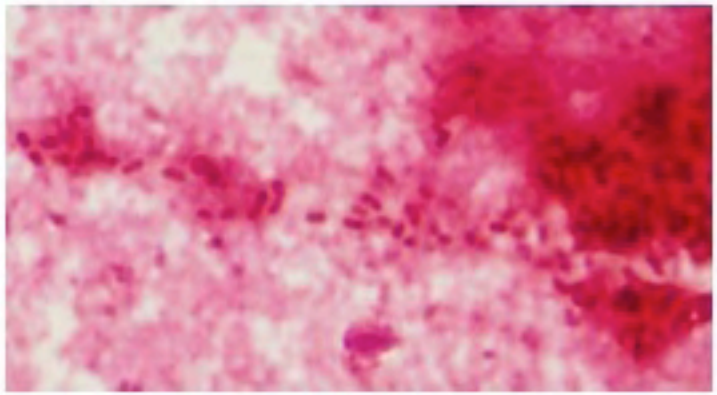

S-IgA response?

Johansen 2009

Biofilm - from the respiratory zone = aerobic niche

Planktonic-

from the conductive zone = anaerobic niche

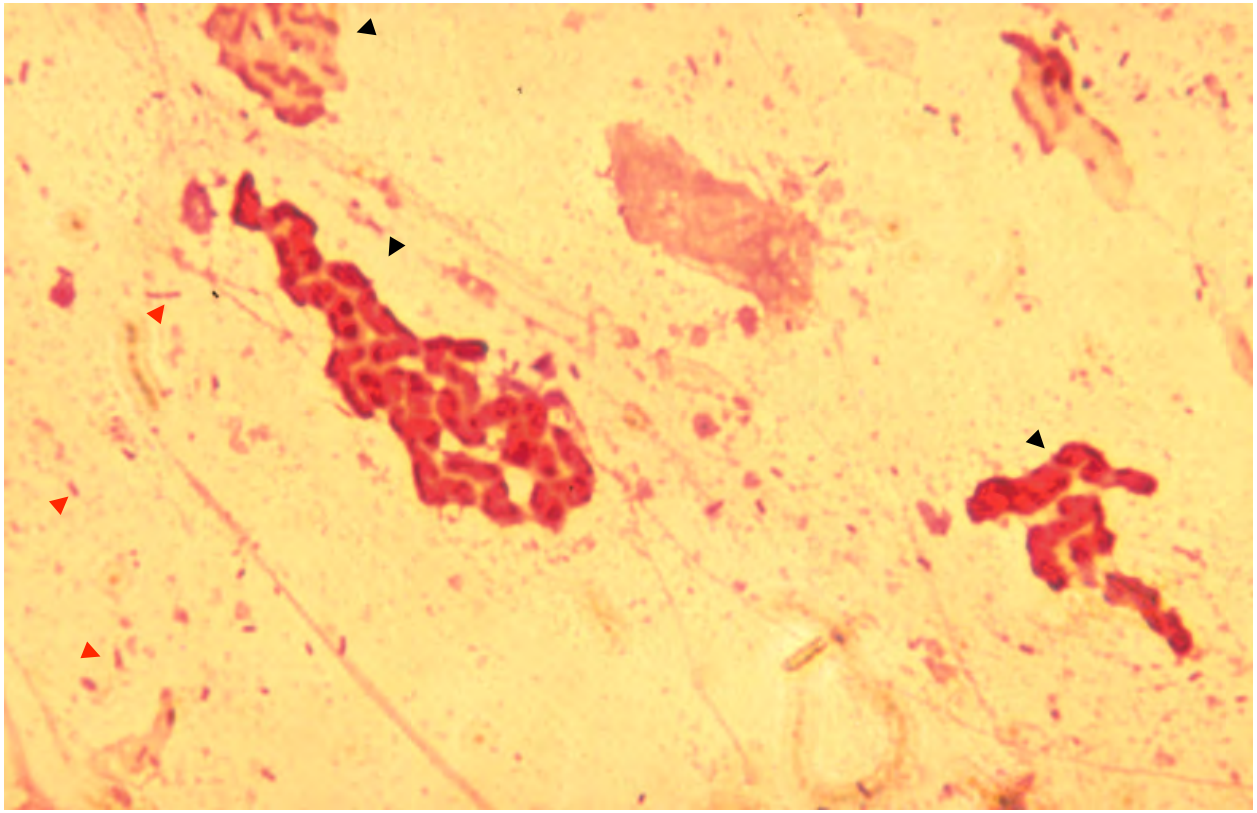

Gram-stained sputum from a CF patient with chronic P. aeruginosa lung infection. 3 black arrows: P. aeruginosa biofilm , 3 red arrows: planktonic P. aeruginosa. Culture revealed both mucoid and non-mucoid colonies. Magnification x 1000.

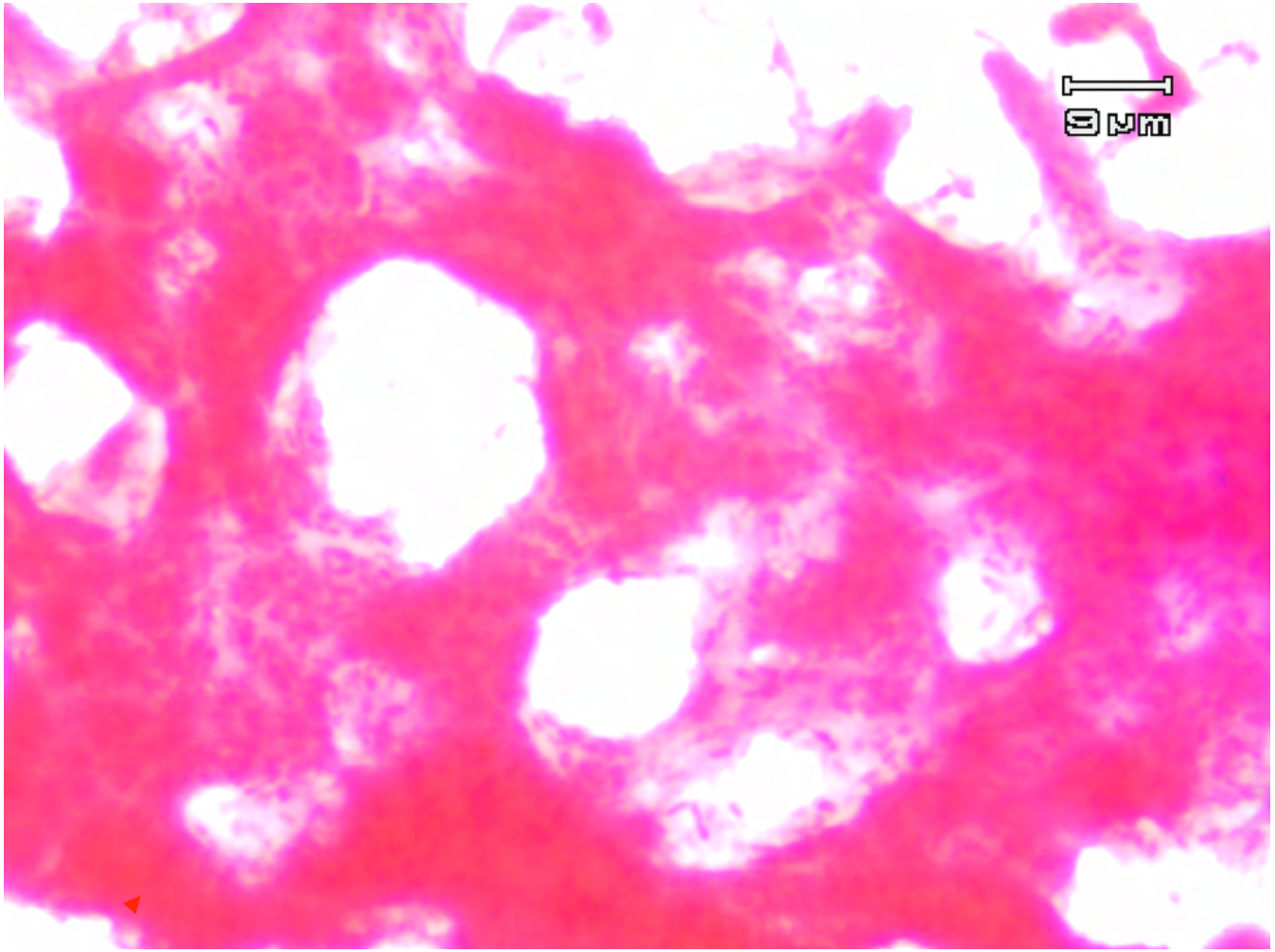

CF sputum - biofilm: **DIVERSITY!** HØIBY 2004

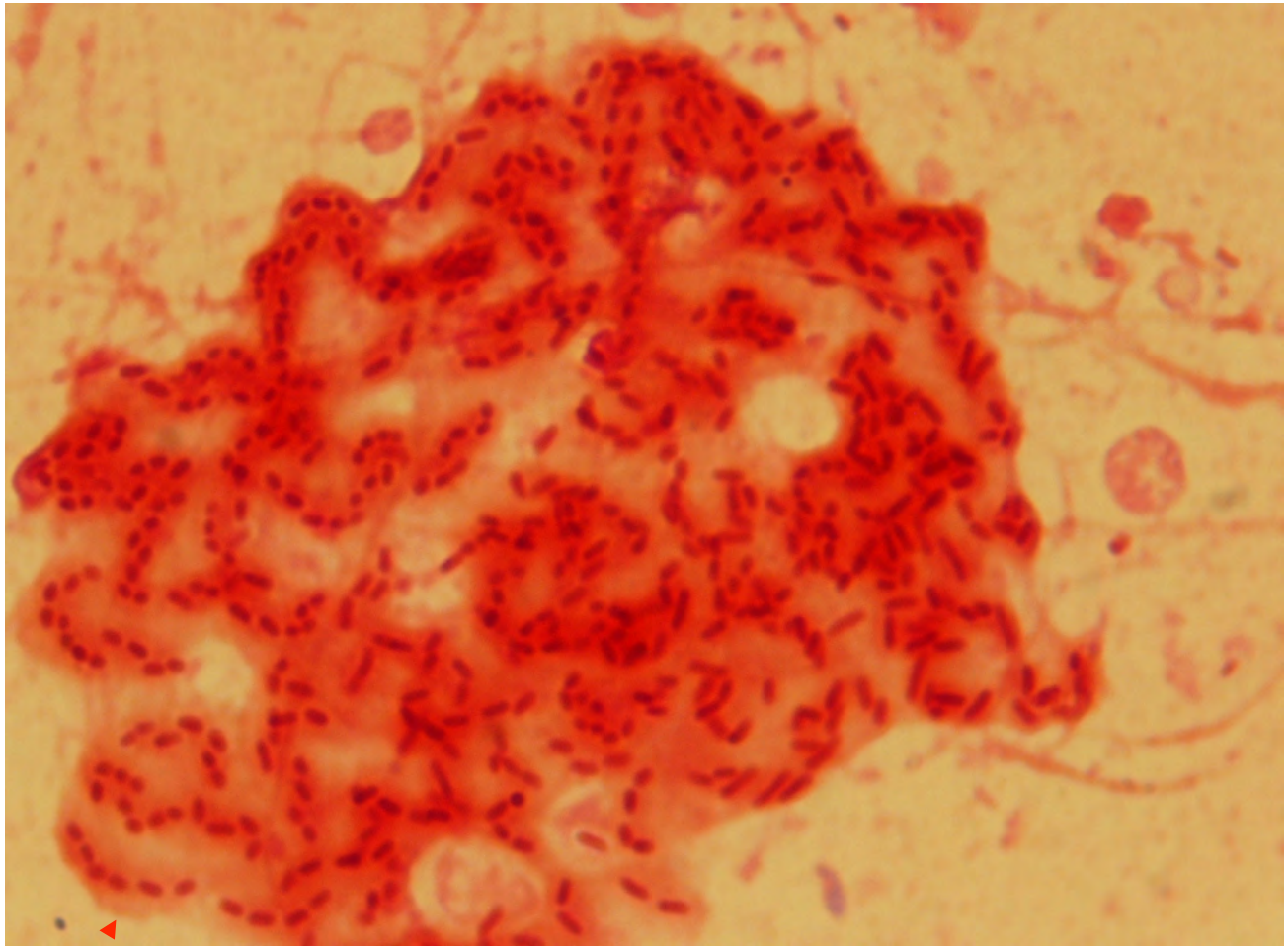

CF sputum - biofilm: **DIVERSITY!** HØIBY 2004



CF sputum - biofilm: **DIVERSITY!** HØIBY

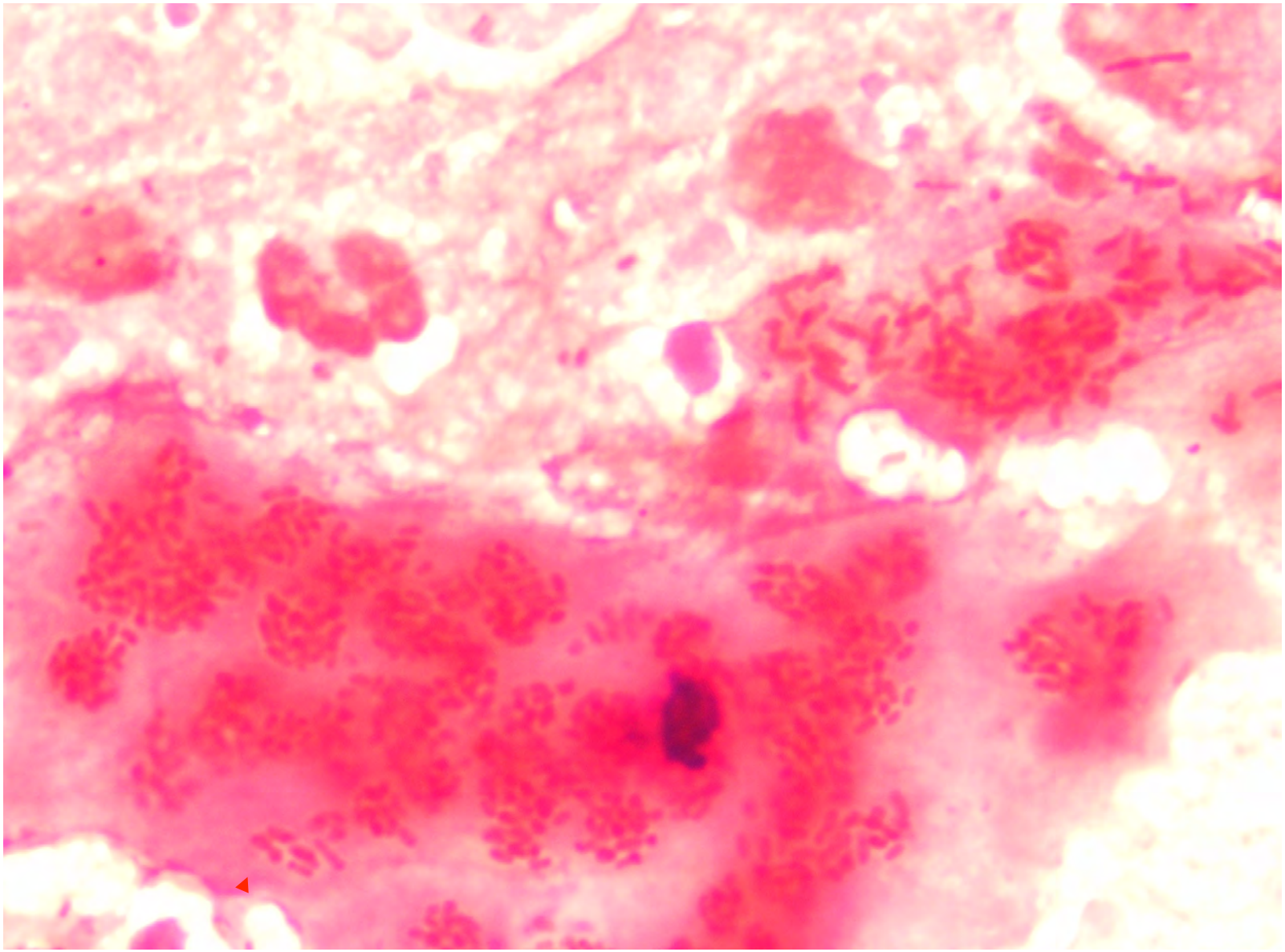

CF sputum - biofilm: **DIVERSITY!**

POLYMORPHONUCLEAR LEUKOCYTES

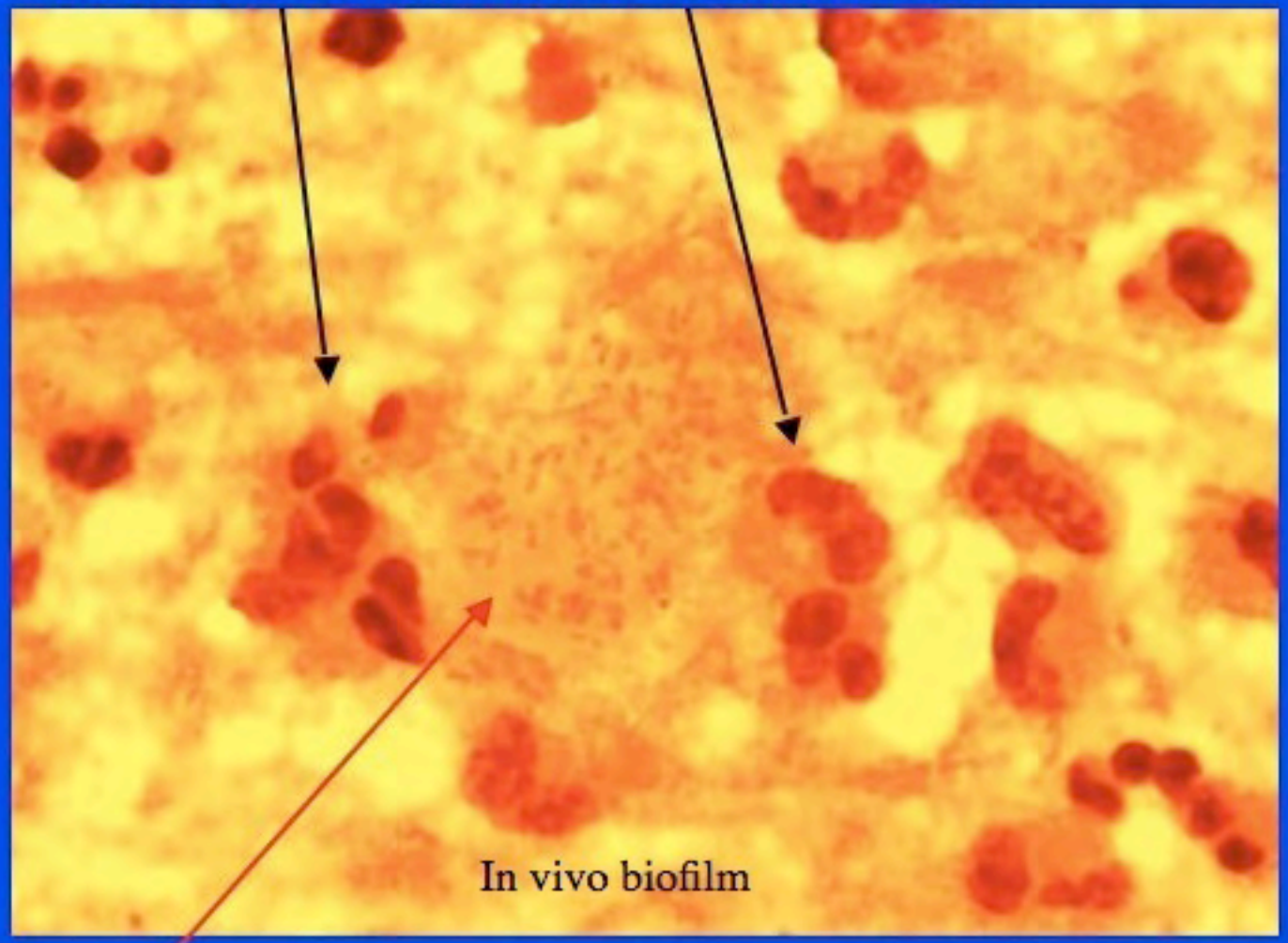

CF sputum - biofilm: **DIVERSITY!**

HØIBY 2004

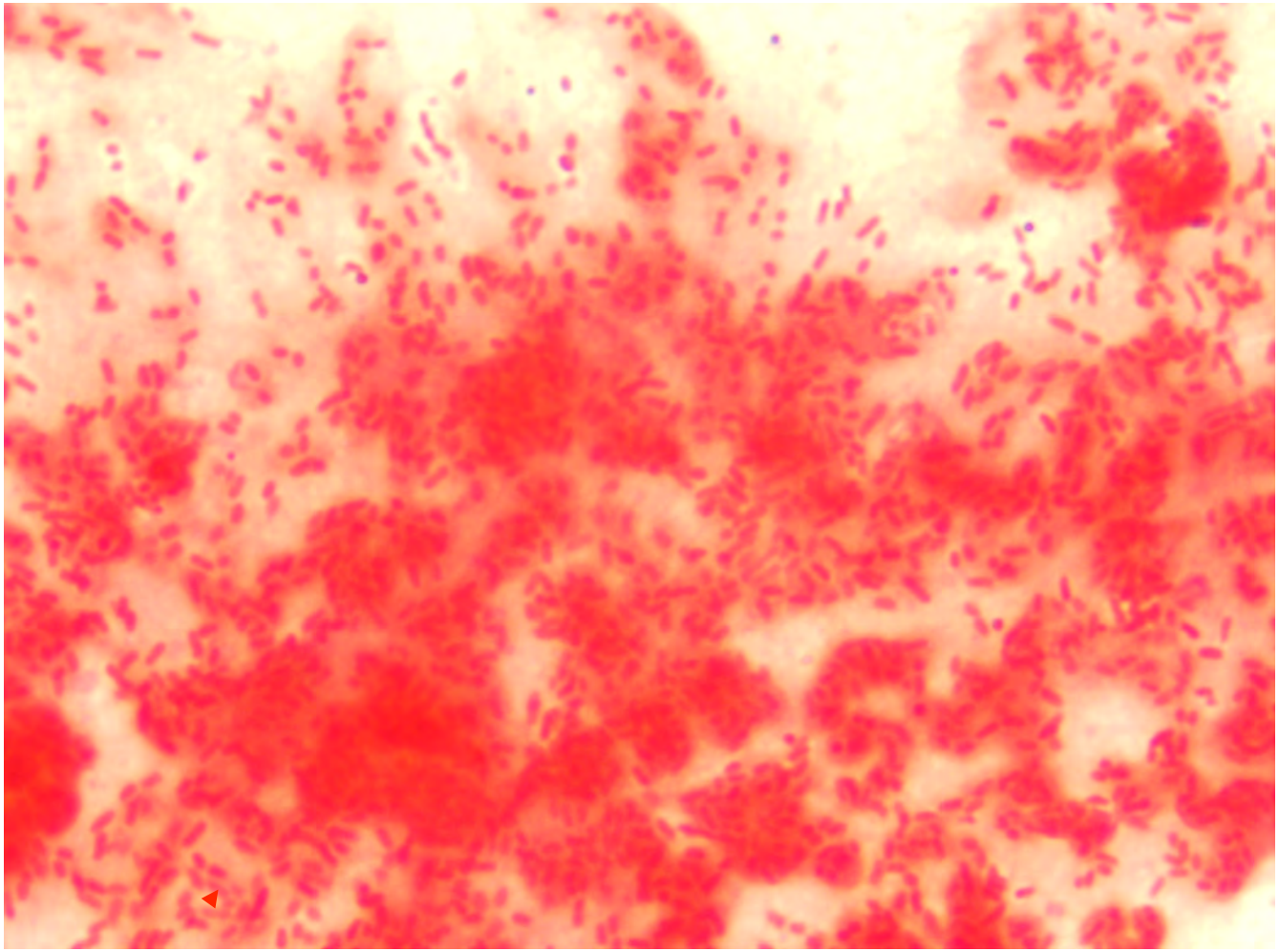

CF sputum - biofilm: **DIVERSITY!** HØIBY 2004

Biofilm in sputum of 14 CF patients with chronic A. xylosoxidans (7/8) or B. multivorans (6/6) lung infection

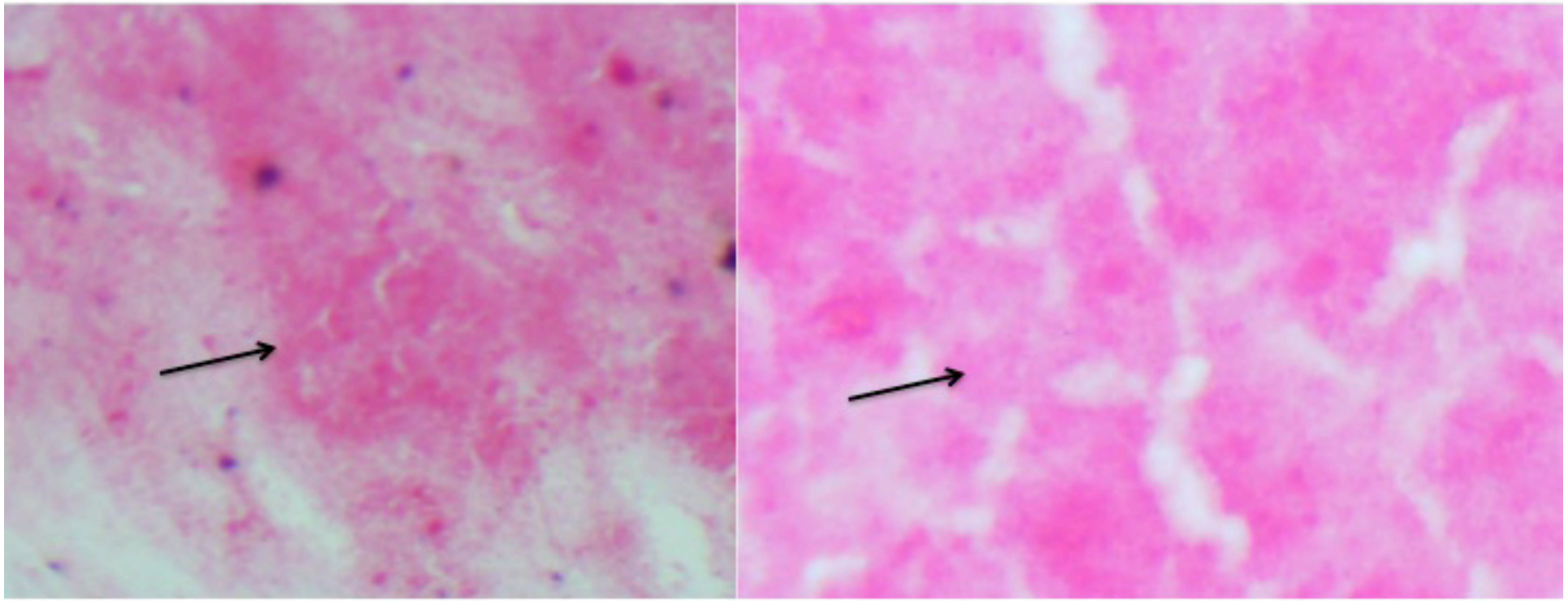

Gram stain x 40 Gram stain x 1000 (Høiby 2009)

Biofilm in Sputum from two CF patients with chronic Stenotrophomonas maltophilia lung infection. Few PMNs

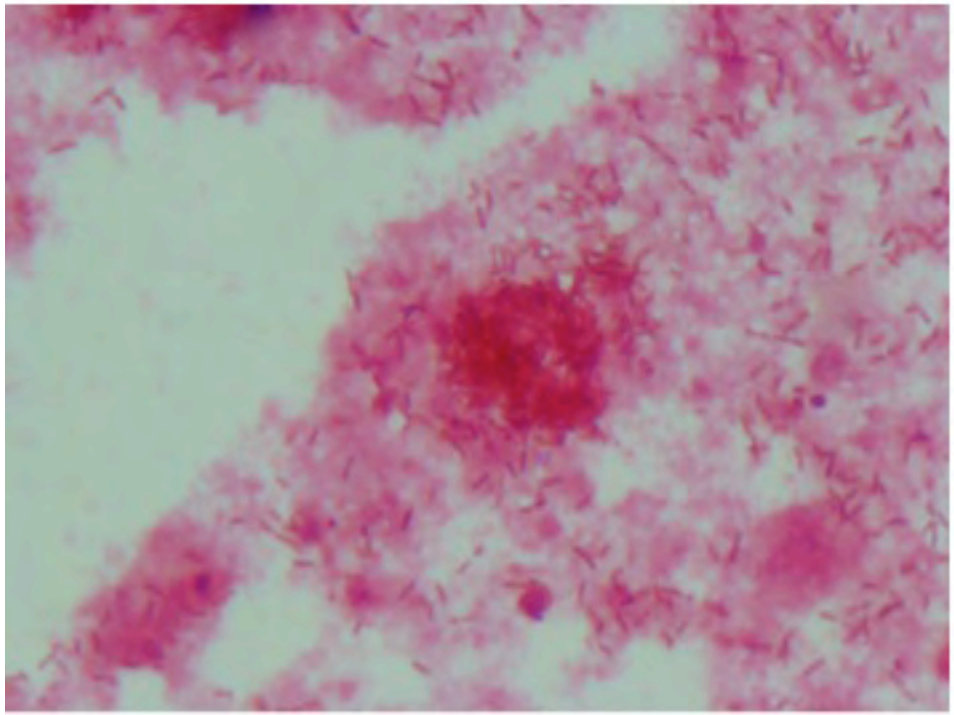

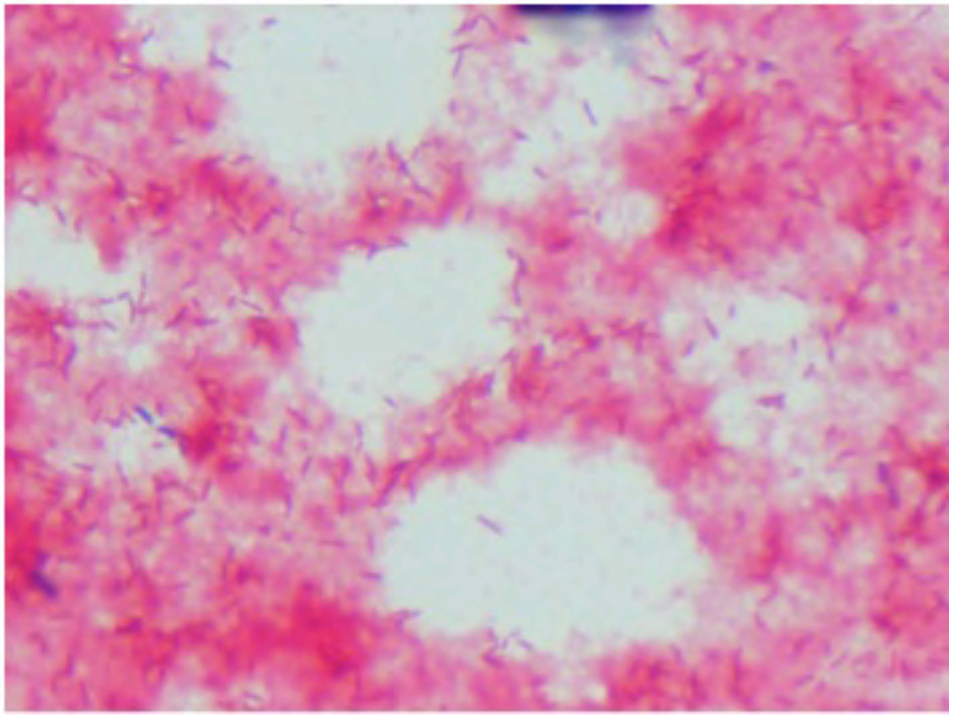

Gram stained smears x 1000

Høiby 2009

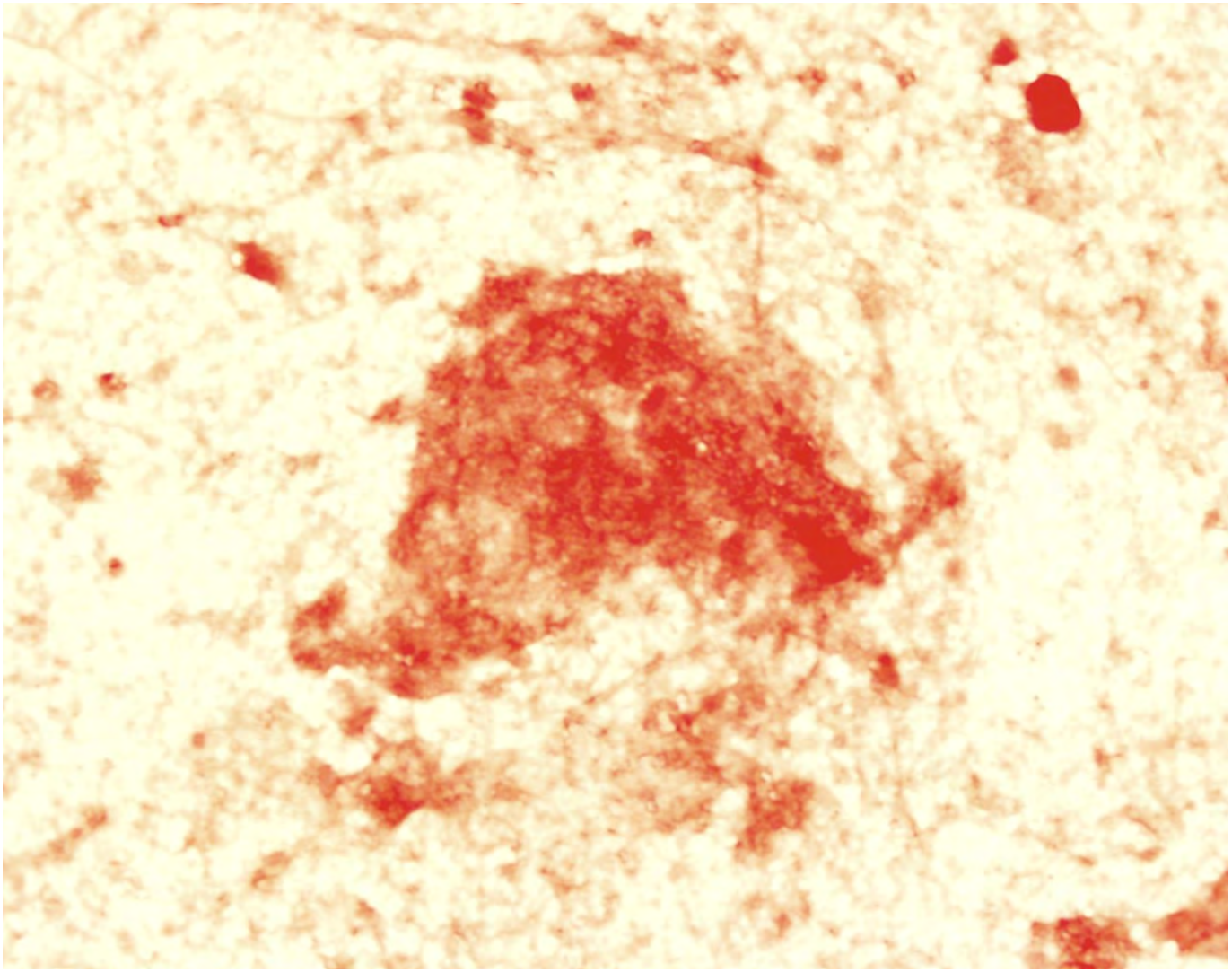

Achromobacter xylosoxidans biofilm in sputum from a chronically infected 23 year old CF patient (CF 370). Gram stain x 1000.

Autopsy of P. aeruginosa infected CF lungs

Høiby 1976

CF lung at autopsy

Pseudomonas in CF patients and CF mice - using the alginate of P. aeruginosa for inoculation

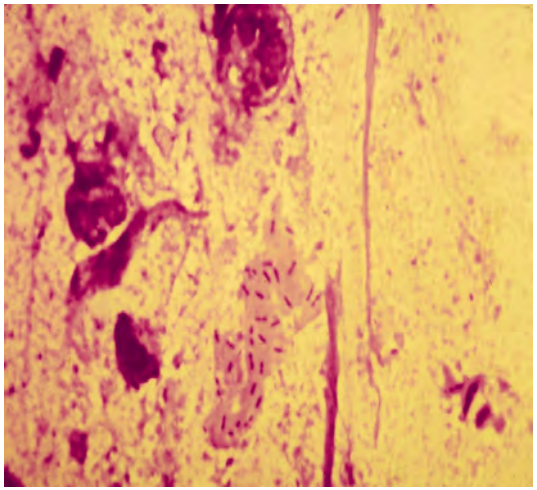

Sputum with a microcolony from a CF patient

CF patient

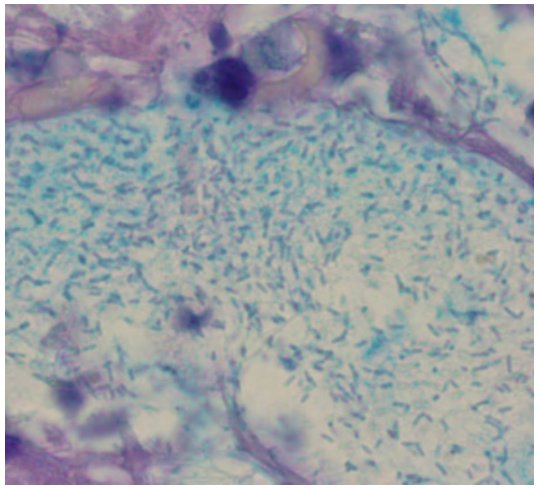

Lung section with a microcolony from a CF mouse



CF mouse



Mucoide P. aeruginosa kolonier



Alginat fra inficerede lunger – alkoholfældet

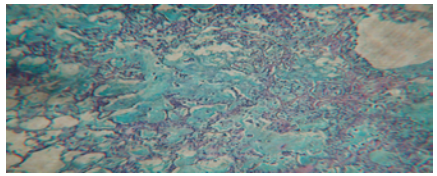

Biofilm i muselunger – farvet med alcian blue for alginat

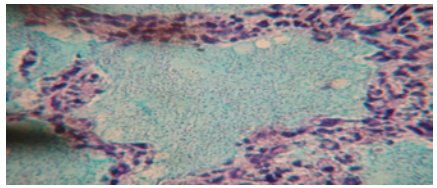

Samme

•Hoffmann, N., Rasmussen, T.B., Jensen, P.Ø., Stub, C., Hentzer, M., Molin, S., Ciofu, O., Givskov, M., Johansen, H.K., Høiby, N.: Novel mouse model of chronic Pseudomonas aeruginosa lung infection mimicking cystic fibrosis. Infect. Immun. 73:2504-14; 2005.

•Hoffmann, N., Lee, B., Hentzer, M., Rasmussen, T.B., Song, Z., Johansen, H.K., Givskov, M., Høiby, N.: Azithromycin blocks quorum sensing and alginat polymer formation and increases the sensitivity to serum and stationary gowth phase killing of P. aeruginosa and attenuates chronic P. aeruginosa lung infection in *Cftr*$^{-/-}$ mice. Antimicr. Agents Chemother. 51:3677-3687; 2007.

•Bjarnsholt, T., Jensen, P.Ø., Fiandaca, M.J., Pedersen, J., Hansen, C.R., Andersen, C.B., Pressler, T., Givskov, M., Høiby, N.: Pseudomonas aeruginosa biofilms in the respiratory tract of cystic fibrosis patients. Pediatric Pulmonology. 44:547-558; 2009.

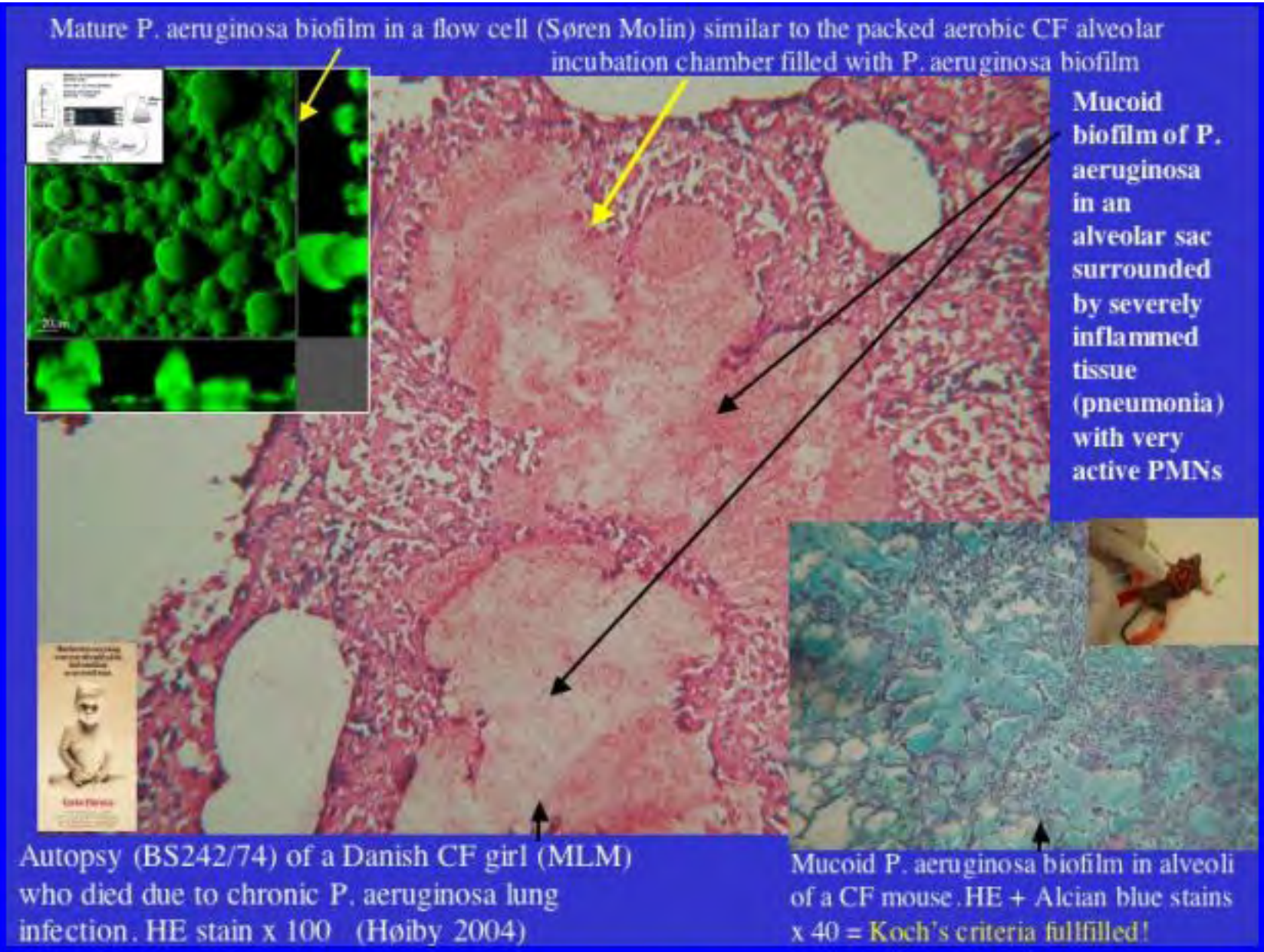

(Hoffmann, Rasmussen, Jensen, Stub, Hentzer, Molin, Ciofu, Givskov, Johansen, Høiby: Novel mouse model of chronic Pseudomonas aeruginosa lung infection mimicking cystic fibrosis. Infect. Immun. 73:2504-14; 2005)

(Hoffmann, N., et al.: Azithromycin blocks quorum sensing and alginat polymer formation and increases the sensitivity to serum and stationary gowth phase killing of P. aeruginosa and attenuates chronic P. aeruginosa lung infection in *Cftr*$^{-/-}$ mice. AAC 51:3677-3687; 2007)

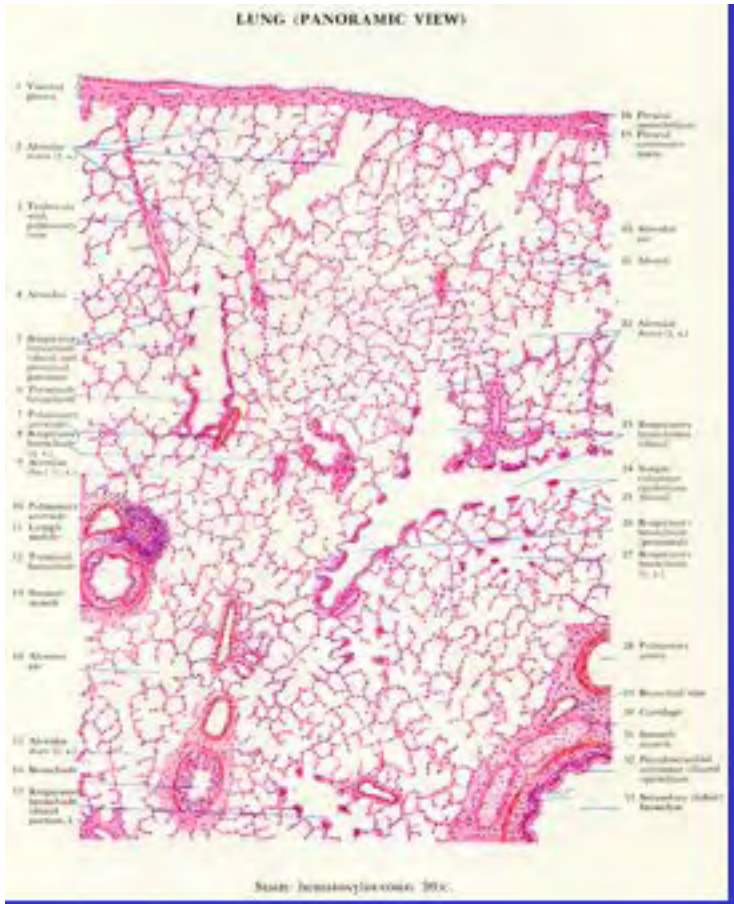

Normal lung

HØIBY 2004

The *packed* aerobic CF alveolar incubation chamber *filled* with mucoid P. aeruginosa biofilm

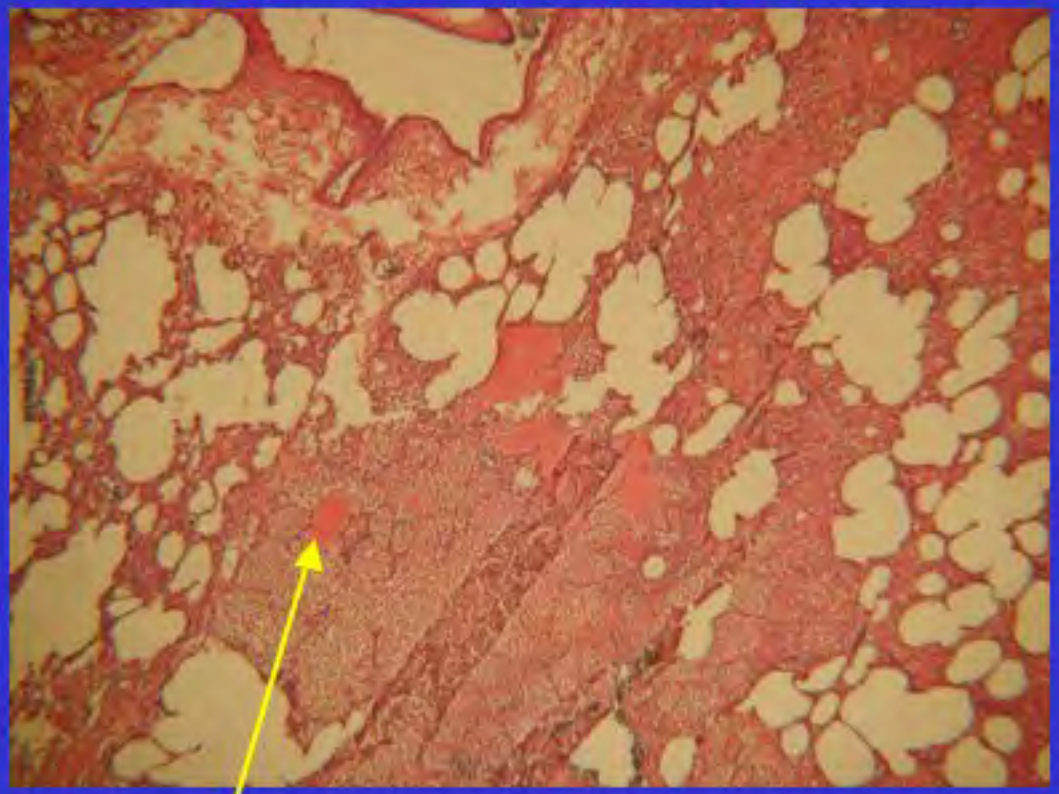

Autopsy (BS242/74) of a Danish CF girl (MLM) who died due to chronic P. aeruginosa lung infection and 21 precipitating antibodies against P. aeruginosa (normal: 0-1). Severely inflammed tisssue (pneumonia). HE stain x 40.

The *packed* aerobic CF alveolar incubation chamber *filled* with mucoid P. aeruginosa biofilm

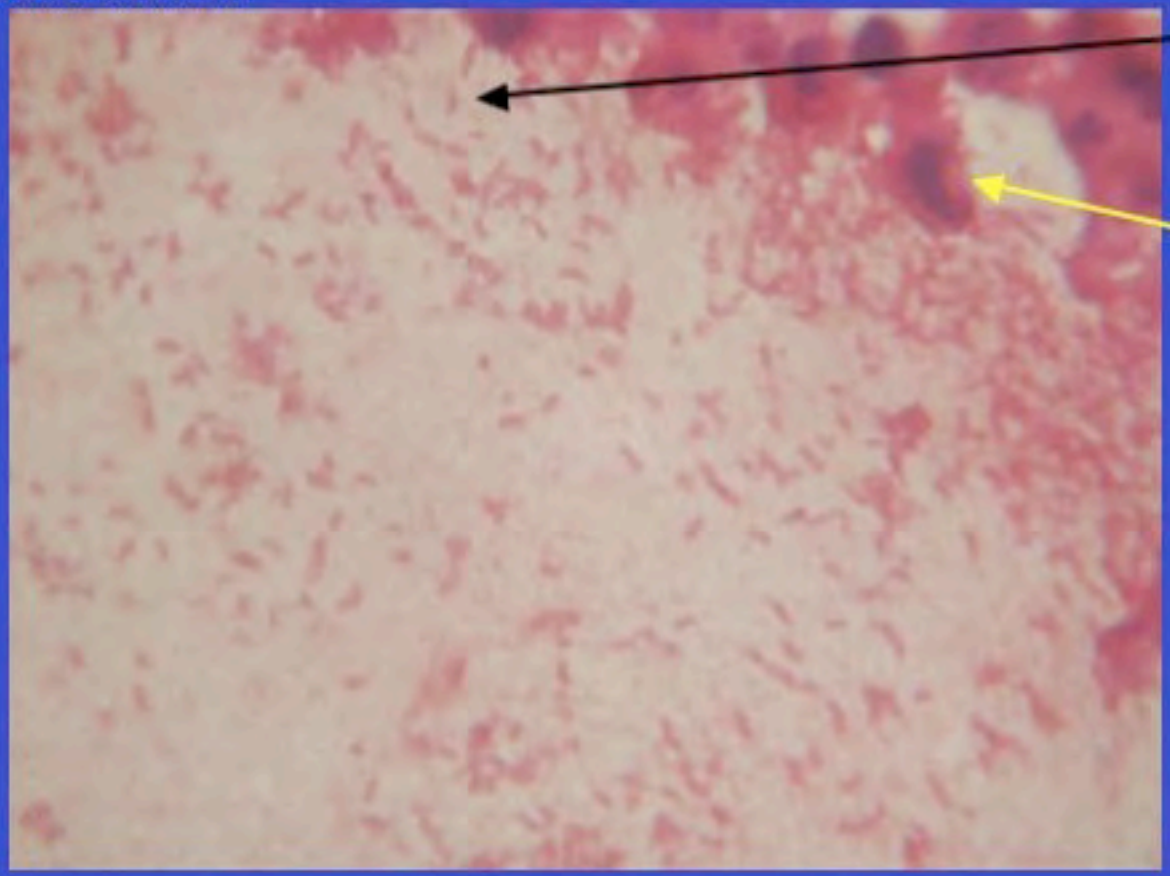

Mucoid biofilm of P. aeruginosa in an alveole surrounded by severely inflammed tissue (PMNs, pneumonia)

↓

Strong immune response in the respiratory zone

Autopsy (BS242/74) of a Danish CF girl (MLM) who died due to chronic P. aeruginosa lung infection and 21 precipitating antibodies against P. aeruginosa. HE stain x 1000

HØIBY 2004